

Treatment of grade four hemorrhoids in a patient with acute myeloid leukemia with severe thrombocytopenia by laser hemorrhoidopexy: A case report

Neeraj Goyal*, Shraiya Tiwari

*From Professor, Department of General Surgery, Max Super Speciality Hospital, Patparganj, New Delhi, India

ABSTRACT

Here, we present the case of a 66-year-old female patient with acute myeloid leukemia and severe thrombocytopenia who came with the complaints of painful per anal mass and bleeding per rectum for 1 year. The patient is a known case of hypertension, and diabetes mellitus and has received three cycles of chemotherapy with decitabine. On examination, she was found to have fourth-degree hemorrhoids at 3, 7, and 11 o'clock positions with acute edematous changes. We successfully treated this patient with laser hemorrhoidopexy, whereby laser energy was delivered to each hemorrhoidal cushion. While lasers for the successful treatment of grade 2 and 3 hemorrhoids are well documented in the literature, we successfully treated this patient with prolapsing fourth-degree hemorrhoids with just laser energy delivery. With these results, we would also like to consider laser hemorrhoidopexy as an effective treatment option for four-degree hemorrhoids for which open Milligan–Morgan hemorrhoidectomy and stapler hemorrhoidectomy are currently considered treatment options.

Keywords: Acute myeloid leukemia, Hemorrhoids, Laser hemorrhoidopexy, Pain, Thrombocytopenia

Hemorrhoids are submucosal cushions containing venules, arterioles, and smooth muscle fibers. They are associated with the vascular theory of arterial hyper flow causing dilations in the hemorrhoidal plexuses and consequently venous hyperplasia and congestion [1]. Along with the internal and external sphincters, they are essential in the maintenance of anal continence by providing soft tissue support and keeping the anal canal tightly closed [2]. These non-surgical options are primarily considered for grade one to three hemorrhoids [3], whereas surgical techniques such as excisional hemorrhoidectomy are suitable for grade 3 and 4 hemorrhoids, and they may be open (Milligan–Morgan) or closed (Ferguson). Milligan–Morgan is still considered the gold standard treatment for symptomatic prolapsing hemorrhoids [4]. However, it is fraught with significant post-operative pain and other complications such as urinary retention, bleeding, anal stenosis, and chronic fissure, making it extremely uncomfortable for the patients and resulting in their reluctance for surgery.


Laser hemorrhoidopexy is a newly developed minimally invasive technique for the treatment of symptomatic hemorrhoids, which involves the delivery of laser energy into the submucosa of the hemorrhoidal cushion. The thermal energy delivered

causes photocoagulation of the hemorrhoidal artery and plexus, thus reducing their blood flow and influencing the shrinkage of hemorrhoids and fibrosis. The fibrotic reconstruction generates new connective tissue, enabling the mucosa to adhere to the underlying tissue, thus preventing the recurrence of prolapse. We thus prefer to use the term hemorrhoidopexy over hemorrhoidoplasty as the suffix “-pexy” in medical terms means fixation or suspension, whereas the suffix “-plasty” means surgical repair. Lasers are not used for repair; the fibrosis instead fixes the hemorrhoidal cushion to the underlying tissue. Available literature suggests that laser hemorrhoidopexy is suitable for lower-grade hemorrhoids (Grades 2 and 3) with low rates of recurrence [5]. However, the long-term outcomes of Grade 4 hemorrhoids being managed by laser are understudied.

We present a case of Grade 4 hemorrhoids being successfully managed in a patient with acute myeloid leukemia (AML) with multiple comorbidities by laser hemorrhoidopexy.

CASE REPORT

A 66-year-old female presented with complaints of bleeding per rectum and a painful mass protruding from the anus for 1 year, interfering with her daily activities. She had been taking conservative management for the same in the form of analgesics and rectal cream but to no benefit. She is a known case of

Access this article online	
Received - 26 March 2023 Initial Review - 08 April 2023 Accepted - 15 May 2023	Quick Response code 
DOI: ***	

Correspondence to: Neeraj Goyal, Max Super Speciality Hospital, Patparganj, New Delhi, India. E-mail: surgeon.neerajgoyal@gmail.com

© 2023 Creative Commons Attribution-NonCommercial 4.0 International License (CC BY-NC-ND 4.0).

hypertension, diabetes mellitus, and AML and has completed three cycles of chemotherapy with decitabine for the same.

The patient was of average build and vitally stable. On diagnosis, the patient was found to have large, prolapsing grade 4 hemorrhoids at 3, 7, and 11 o'clock positions with acute edematous changes.

On further workup, she was found to have anemia (hemoglobin 6 g/dL) and thrombocytopenia (platelet count 8,000/mL). On the peripheral smear, blast cells were present. Her blood group was B-negative. We optimized the patient for surgery by preoperative packed RBC and platelet transfusion (Fig. 1a).

Under general anesthesia, in a lithotomy position, the patient was taken up for laser hemorrhoidopexy. Routine antibiotic prophylaxis was given. No intestinal preparation was given, just a generous dose of laxatives for 3 days before surgery. We used Lasotronix (Poland) 1470 nm diode laser, bare fiber and delivered energy to each hemorrhoid (3, 7, and 11 o'clock) at 8W, continuous mode, approximately 350 J per hemorrhoid (Fig. 1b). After inserting the anoscope, we first sprayed approximately 60 J of energy intraluminally, at an area 2×2 cm above the apex of the hemorrhoid. Then, by piercing through the groove between the two anal sphincters, we delivered around 70 J of energy submucosally in the same 2×2 m area above the apex of hemorrhoid. This was followed by around 150 J of energy delivery within the hemorrhoidal mass, followed by ice application for 1 min. A similar procedure was repeated for the other two hemorrhoids as well. There was minor bleeding from the laser fiber prick site, which was controlled by external compression for 2 min.

The patient was allowed a soft diet after 4 h and was administered an intravenous paracetamol injection of 1000 mg every 8 h postoperatively. She was discharged the following morning on oral diclofenac 50 mg tablets every 8 hours for 1 week. Post-operative pain follow-up was performed using

a visual analog scale (VAS) (0-no pain and 10-worst pain). On the postoperative day 1, the patient had a VAS of 5/10, there was no per anal bleeding and the hemorrhoids had shrunk a bit. She returned to daily activities 3 days after surgery. On the postoperative day 7, she had a VAS of 2/10 with a further decrease in the size of hemorrhoids and no complaints of per anal bleeding. On the postoperative day 14, her pain score was 0/10 and her hemorrhoids had shrunk significantly. At the 6-week follow-up, her hemorrhoids had completely resolved and she was experiencing no pain, no bleeding, and no difficulty during bowel movements (Fig. 2a-c). At 3-month, 6-month, and 1-year post-surgery follow-up, there were no complaints from the patient or any recurrence. Unfortunately, we lost her to follow-up as the patient succumbed to her malignancy.

DISCUSSION

Hemorrhoids are the most common colorectal disease affecting the urban population. The most common symptoms associated with it are bleeding, pain, prolapse, and mucosal discharge. They can cause significant distress for the patient and are a major medical and socioeconomic problem. Hemorrhoids are graded into four grades. Grade 1 is an enlarged vein seen on anoscopic examination. Grade 2 has prolapsing hemorrhoids that are reducing spontaneously. Grade 3 is prolapsing but requires manual reduction and Grade 4 is irreducible [6].

There are many methods of treatment of hemorrhoids ranging from conservative medical management, and non-excisional therapies to stapler hemorrhoidopexy and excisional hemorrhoidectomies. Symptomatic hemorrhoids that have failed conservative medical management are considered for other therapies. Milligan-Morgan hemorrhoidectomy is considered the gold standard treatment for hemorrhoids with a low rate of recurrence and the most frequently performed procedure for grade 3 and 4 hemorrhoids. However, it is fraught with complications such as significant postoperative pain, urinary retention, abscess formation, fistula, and anal stenosis. Despite the range of treatment options available, postoperative pain remains the key concern in the management of symptomatic hemorrhoid disease.

Hemorrhoidal disease is associated with the vascular theory of arterial blood overflow causing dilation in the hemorrhoidal plexuses and, consequently, venous hyperplasia

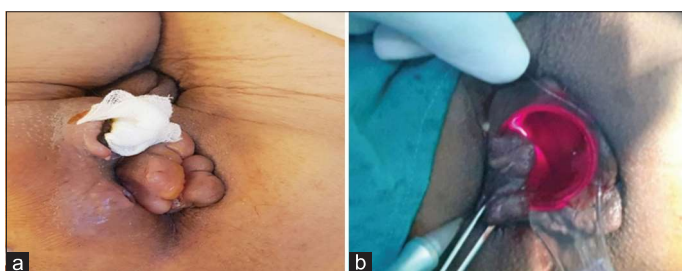


Figure 1: (a) Preoperative; (b) Laser energy being delivered to the patient

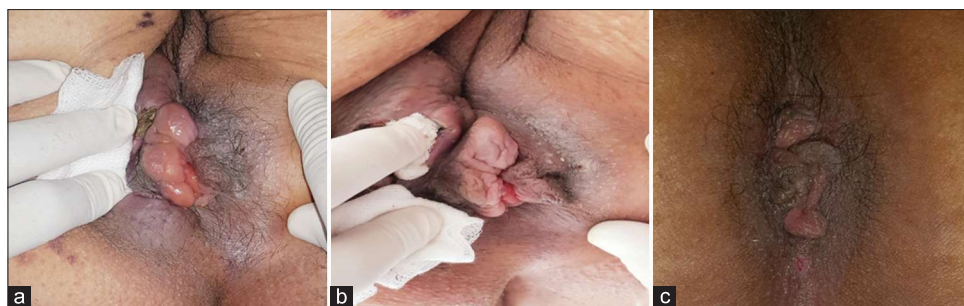

Figure 2: Post-operative (a) day 7 follow-up (b) day 14 follow-up and (c) 6-week follow-up

and congestion [1,7]. It is based on the anatomical finding of arteriovenous hemorrhoidal shunting with no capillary interposition. The use of lasers in proctology began in the 1960 s, when the Nd: YAG laser was first used for anorectal surgery. After that, new lasers, such as diode lasers and CO₂ lasers with pulsed and continuous modes, were introduced and resulted in improved outcomes [8,9]. Laser hemorrhoidopexy involves the use of diode lasers and aims to interrupt the flow in the terminal arterioles by photocoagulation. It causes tissue shrinkage and degeneration at different depths according to the laser power and the duration of the application of the laser beam. It results in gradual fibrosis of the hemorrhoidal tissue for 4–6 weeks. Due to the lack of vascular supply to the pile mass, there is a significant reduction in the size of the hemorrhoid and betterment of symptoms. This supports the vascular theory of the pathogenesis of hemorrhoids. In our case, laser energy was delivered in the hemorrhoidal cushion as well as the area above the apex of hemorrhoids where the arteries lie. Laser coagulation of vessels has the advantage of conserving the anatomy and physiology of the anal canal, which minimizes postoperative impaired anal function as compared to other forms of treatment [10]. It does not involve any tissue excision thus, minimizing the post-operative pain. Due to the highly selective effect of laser beams on arteries, they cause minimum damage to the surrounding area [11]. Literature supports the use of laser therapy for those with 2nd/3rd hemorrhoids with minimal to moderate rectal prolapse [12].

Ram *et al.* [12] carried out a study on 58 patients with second and third-degree hemorrhoids who underwent laser hemorrhoidopexy. Postoperative pain was noted to be VAS 0 in 80.6% of the patients at first defecation, VAS 0 in 82.3% of the patients at the 1st week, and VAS 0 in 95.2% of the patients at 1 month. Post-operative abscess formation was 5%, and urine retention was 20.1%. Long-term complications were fissure (2.6%), anal stenosis (1%), incontinence (0.4%), and fistula (0.5%). Bruscianno *et al.* [13] conducted a study on 50 patients who underwent laser hemorrhoidopexy. No cases of spontaneous bleeding after surgery occurred, while 32 (60%) patients experienced post-defecatory bleeding only on the 1st day after surgery and 15 (30%) patients on the postoperative day 3, but in all cases, the bleeding episodes stopped from the 7th postoperative day.

However, the long-term outcomes of Grade 4 hemorrhoids have been understudied in the literature. In our case, we have successfully used lasers to treat large, Grade 4 hemorrhoids without any mucopexy or tissue excision. Our patient presented to us with large, prolapsing grade four hemorrhoids associated with significant discomfort while sitting or carrying out daily activities. They were also associated with frequent episodes of per-rectal bleeding. Our patient was a known case of AML with thrombocytopenia who had completed three cycles of chemotherapy with decitabine. This made her management tricky as patients with AML are prone to bleeding and excessive bruising. We decided not to go with conventional hemorrhoidectomy and instead treated her with laser hemorrhoidopexy. With lasers, we provided her with the benefits of no tissue excision, thus minimal bleeding, and no external wound; hence, no dressings

were required. A traditional hemorrhoidectomy in this patient would have resulted in excessive bleeding and an external wound which would have caused problems with healing due to the immunocompromised condition of the patient. It would have also caused a painful postoperative recovery owing to the large raw surface area after excision and the further late postoperative complication of anal stenosis. Since laser treatment can be repeated multiple times, we had told the patient prior that she may require additional doses of laser therapy as she had large hemorrhoidal masses, but to our surprise, her hemorrhoids resolved really well and no additional doses were required.

Although it is a high-cost technique, it has very satisfactory short- and long-term results. This procedure, though decreases the duration of the hospital stay and thus decreases the amount spent on overall treatment. Comparative studies with other existing techniques have reported a higher index of patient satisfaction because of lesser postoperative pain, satisfactory symptom relief, and recurrence rates on long-term follow-up [14,15].

CONCLUSION

Laser hemorrhoidopexy is an effective, safe, almost painless, easy-to-perform technique with a short hospital stay and is an efficient substitute for open hemorrhoidectomy, even for grade 4 hemorrhoids, with the advantages of no tissue excision, greater precision, and hence, lesser postoperative pain and other complications. In patients with comorbidities and immunocompromised status, this minimally invasive treatment is a boon and should be considered instead of conventional hemorrhoidectomy.

REFERENCES

1. Ratto C, Donisi L, Parello A, Litta F, Doglietto GB. Evaluation of transanal hemorrhoidal dearterialization as a minimally invasive therapeutic approach to hemorrhoids. *Dis Colon Rectum* 2010;53:803-11.
2. Maloku H, Gashi Z, Lazovic R, Islami H, Juniku-Shkololli A. Laser hemorrhoidoplasty procedure vs open surgical hemorrhoidectomy: A trial comparing 2 treatments for hemorrhoids of third and fourth degree. *Acta Inform Med* 2014;22:365-7.
3. MacRae HM, McLeod RS. Comparison of hemorrhoidal treatment modalities. *Dis Colon Rectum* 1995;38:687-94.
4. Gallo G, Luc AR, Clerico G, Trompetto M. Diathermy excisional haemorrhoidectomy - still the gold standard - a video vignette. *Colorectal Dis* 2018;20:1154-6.
5. Longchamp G, Liot E, Meyer J, Toso C, Buchs NC, Ris F. Non-excisional laser therapies for hemorrhoidal disease: A systematic review of the literature. *Lasers Med Sci* 2021;36:485-96.
6. Chung YC, Hou YC, Pan AH. Endoglin (CD105) expression in the development of haemorrhoids. *Eur J Clin Investig* 2004;34:107-12.
7. Pata F, Gallo G, Pellino G, Vigorita V, Podda M, Di Saverio S, *et al.* Evolution of surgical management of hemorrhoidal disease: An historical overview. *Front Surg* 2021;8:727059.
8. Chia Y, Darzi A, Speakman C, Hill A, Jameson J, Henry M. CO₂ laser haemorrhoidectomy--does it alter anorectal function or decrease pain compared to conventional haemorrhoidectomy? *Int J Colorectal Dis* 1995;10:22-4.
9. Senagore A, Mazier WP, Luchtfeld MA, MacKeigan JM, Wengert T. Treatment of advanced hemorrhoidal disease: A prospective, randomized comparison of cold scalpel vs. contact Nd: YAG laser. *Dis Colon Rectum* 1993;36:1042-9.

10. Ferguson JA, Heaton JR. Closed hemorrhoidectomy. *Dis Colon Rectum* 1959;2:176-9.
11. Ng KS, Holzgang M, Young C. Still a case of “no pain, no gain”? An updated and critical review of the pathogenesis, diagnosis, and management options for hemorrhoids in 2020. *Ann Coloproctol* 2020;36:133-47.
12. Ram E, Bachar GN, Goldes Y, Joubran S, Rath-Wolfson L. Modified Doppler-guided laser procedure for the treatment of second-and third-degree hemorrhoids. *Laser Ther* 2018;27:137-42.
13. Brusciano L, Gambardella C, Terracciano G, Gualtieri G, di Visconte MS, Tolone S, *et al.* Postoperative discomfort and pain in the management of hemorrhoidal disease: Laser hemorrhoidoplasty, a minimal invasive treatment of symptomatic hemorrhoids. *Updates Surg* 2020;72:851-7.
14. Lakmal K, Basnayake O, Jayarajah U, Samarasekera DN. Clinical outcomes and effectiveness of laser treatment for hemorrhoids: A systematic review. *World J Surg* 2021;45:1222-36.
15. Giamundo P. Advantages and limits of hemorrhoidal dearterialization in the treatment of symptomatic hemorrhoids. *World J Gastrointest Surg* 2016;8:1-4.

Funding: Nil; Conflicts of interest: Nil.

How to cite this article: Goyal N, Tiwari S. Treatment of grade four hemorrhoids in a patient with acute myeloid leukemia with severe thrombocytopenia by laser hemorrhoidopexy: A case report. *Indian J Case Reports*. 2023; May 31 [Epub ahead of print].